



GREYHOUNDS HEALTH AND WELLNESS QUARTERLY



COLLEGE OF
VETERINARY MEDICINE



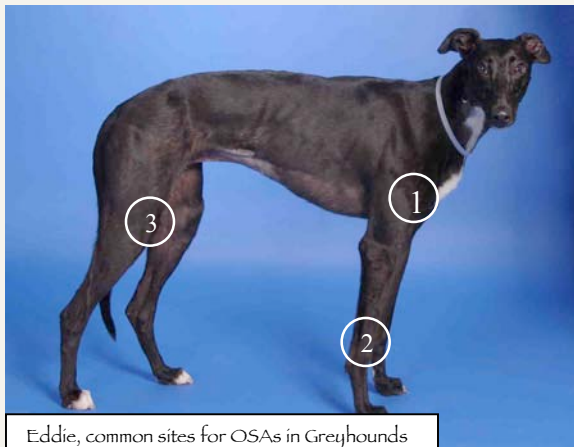G
R
E
Y
H
O
U
N
D
S

BONE TUMORS IN GREYHOUNDS

Primary bone neoplasms are common in dogs. Most primary bone tumors in dogs are malignant, in that they usually cause death as a result of local infiltration (e.g., pathologic fractures or extreme pain leading to euthanasia) or metastasis (e.g., pulmonary metastases in osteosarcoma). Neoplasms that metastasize to the bone are extremely rare in dogs; some malignant tumors that occasionally metastasize to bones are transitional cell carcinoma of the urinary tract, osteosarcoma of the appendicular skeleton, hemangiosarcoma, mammary adenocarcinoma, and prostatic adenocarcinoma.

Osteosarcomas (OSAs) are the most common type of bone cancer in retired racing Greyhounds (45%) and the most common cause of death in the breed (25%). It affects more commonly the front limbs (75%) than the rear limbs (25%) and there is a predilection for males (59%).

The cause of OSA in Greyhounds is unknown, but it has been suggested that the repetitive trauma and fatigue in their bones during racing plays a role in the disease, particularly in the right limbs that sustain most of the weight while running counterclockwise on the tracks. However, there is no significant difference in the proportion of right limb tumors versus left limb tumors in Greyhounds. More studies are needed to determine if their racing careers are a risk for the disease or if there is a genetic component.



Eddie, common sites for OSAs in Greyhounds

OSA in Greyhounds commonly affects:

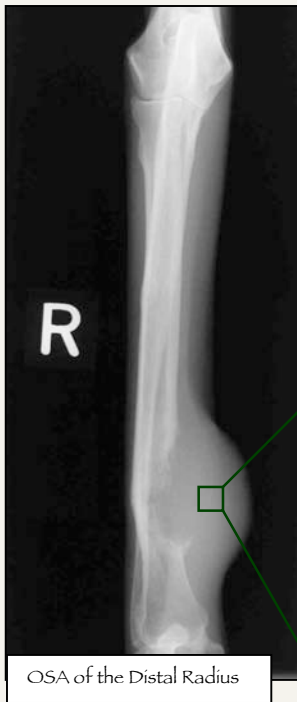1. The upper front leg bone, below the shoulder joint, (proximal humerus).
2. The lower part of the front leg bone, above the wrist joint (distal radius).
3. The lower part of the rear leg bone, above the knee, (distal femur).

“Although, they can affect any bone or location”.

The most common signs in dogs with bone tumors are limping and/or swelling. The onset of signs is variable, and the degree of lameness varies from mild to a non-weight-bearing lameness. In contrast with other breeds, Greyhounds frequently present with a spontaneous pathological fracture without prior history of lameness (1 in 5 cases).

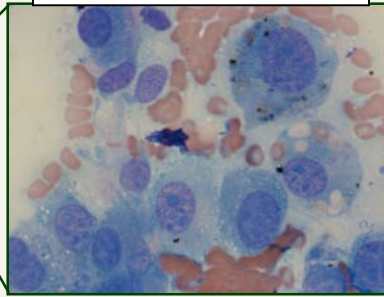
The diagnosis of OSA usually includes radiographs (affected bone and thorax); because other primary bone tumors and some infectious lesions can mimic the radiographic features of OSAs, fine-needle aspiration (FNA) of the lesion may be obtained. We do not recommend biopsy in Greyhounds because we typically do not obtain a diagnostic sample, and because due to the small, fragile bones in the hounds we are more concerned about biopsy-induced fractures.

G
R
E
Y
H
O
U
N
D
S



OSA of the Distal Radius

OSA cells under microscope, 100x.



Radiographically, OSAs exhibit a mixed lytic-proliferative (destruction-production) pattern of the affected bone. Once a presumptive radiographic diagnosis has been established and if the owners are contemplating treatment, thoracic radiographs should be obtained to determine the extent of the disease. We usually obtain three radiographic views of the thorax. Only approximately 10% of dogs with OSA initially have radiographically detectable lung lesions; the presence of metastases is a strong negative prognostic factor.

A fine-needle aspiration (FNA) of the affected area is a simple, painless procedure that rarely requires chemical restraint (i.e.; sedation) and it allows the microscopic analysis of the cells. OSA cells are usually round or oval, have distinct cytoplasmic borders, have a bright blue, granular cytoplasm, and have excentric nuclei with or without nucleoli.

The treatment of choice for dogs with OSA is amputation with adjuvant single-agent or combination chemotherapy. The median survival time in Greyhounds with OSA treated with amputation alone is approximately 4 months, whereas in dogs treated with amputation and chemotherapy (carboplatin or doxorubicin) it is approximately 12-18 months. Here at The Ohio State University, we use either carboplatin or doxorubicin for a total of 4 to 5 treatments, starting the day of the suture removal (8-10 days after amputation), we check the complete blood count (CBC) and chemistry profile before every chemotherapy treatment, and thoracic radiographs every 3 months.

Amputation in Greyhounds with OSA frequently results in severe postoperative bleeding (24-48h post-surgery) starting around the surgical site, leading to subcutaneous blood accumulation in the other limbs, ventral thorax, and ventral abdomen; these dogs typically have normal hemostasis profiles (APTT, OSPT). Administration of aminocaproic acid (Amicar®) usually prevents severe postoperative bleeding.



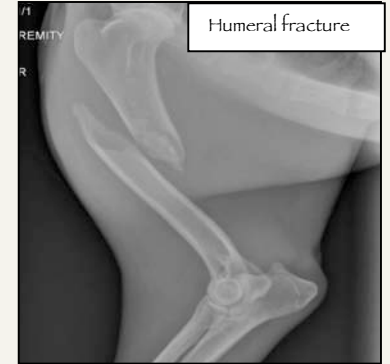Zinger

Less than 20% of dogs undergoing chemotherapy experience clinically relevant adverse effects, which include nausea, vomiting, diarrhea, or loss of appetite. However their frequency and severity are not as high as in humans. The prevalence of adverse effects appears to be lower in Greyhounds than in other dog breeds. These adverse effects are typically managed with medications, chemo drug dose reduction, or changing to a different chemotherapeutic agent.

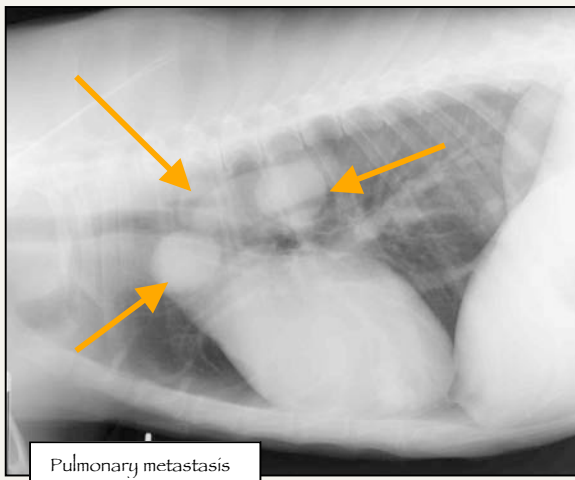
G
R
E
Y
H
O
U
N
D
S

Management of nausea and vomiting episodes is limited to the use of antiemetics and supportive therapy. The drugs of choice are metoclopramide (Reglan®) or maropitant (Cerenia®). Supportive fluid therapy (if necessary) and treatment with bismuth subsalicylate products (Pepto-Bismol®) orally three or four times a day, are usually effective in controlling diarrhea, which usually resolve in 3 to 5 days.

If the dog is not a good candidate for amputation, because of problems in the other limbs or if owners are reluctant to allow the veterinarian to amputate the limb, local radiotherapy plus carboplatin may be of some benefit.



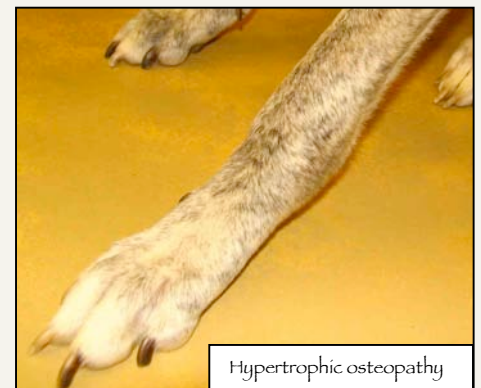Pain control is essential in dogs where surgery is not an option; we have used either NSAIDs (carprofen, deracoxib, meloxicam) at recommended doses, or bisphosphonates such as alendronate (Fosamax®), or pamidronate (Aredia®), every 3 to 6 weeks. Drugs such as tramadol (Ultram) may also be beneficial.



Dogs with pulmonary metastases typically do not show any signs; radiographs are the only way to detect the nodules, which can be single or multiple.

Surgical removal of the metastatic pulmonary nodules (i.e., metastasectomy) followed by additional carboplatin or doxorubicin therapy may be recommended for a dog that has been treated with chemotherapy after amputation of the limb and in which one to three pulmonary metastatic lesions are detected.

A secondary syndrome seen in some Greyhounds with pulmonary metastasis is *hypertrophic osteopathy* (HO), which is a bilateral, symmetrical soft tissue swelling of the lower legs. The limbs may be warm to the touch and are often painful when pressed. Unfortunately, when there is evidence of metastatic disease, the prognosis is poor.

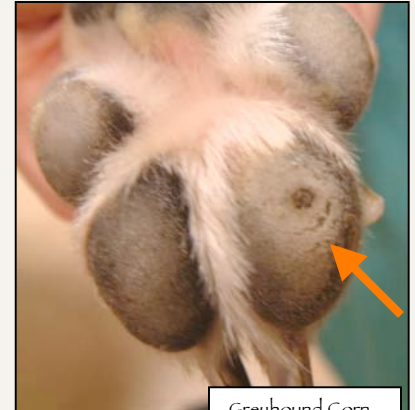

Here at OSU, by the time of detection of metastasis we use metronomic therapy (low doses of chemotherapy and other drugs); we use cyclophosphamide every other day, piroxicam every other day, and artemisinin, an herbal drug with antitumor effects. We have had excellent results with artemisinin with OSA cells in the test tube.

CORNS IN GREYHOUNDS

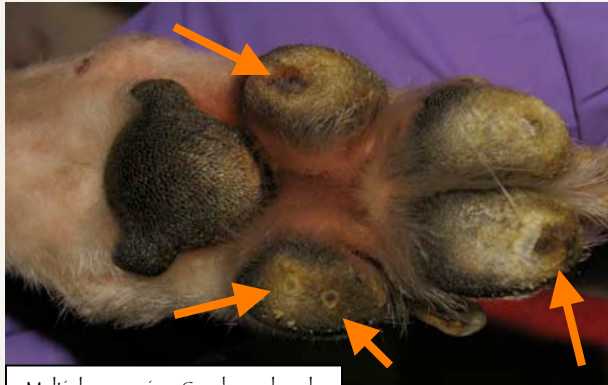
Corns are a very common finding in the pads of the Greyhounds; they can be single or multiple, and may or may not cause pain and/or severe lameness.

Since Greyhounds have a high prevalence of bone cancer, owners and vets frequently spend a considerable amount of time and money in orthopedic consults and bone radiographs, trying to find a reason for their Greyhound is limping, and sometimes a simple thing as a corn is missed.



Greyhound Corn

There are numerous reported ways to treat corns. Everything from application of duct tape to the corn to toe amputation has been reported. We currently use a hulling technique, sometimes followed by the application of the anti-wart medication Aldara® or Abreva®. The hulling procedure will need to be repeated as often as every 3 weeks although we have had some corns fail to re-grow following several treatments.



Multiple corns in a Greyhound pad

You can consult the following articles for more information on corns and hulling:

http://www.grassmere-animal-hospital.com/corn_hulling.htm

<http://www.grassmere-animal-hospital.com/corns.htm>

WE DEPEND ON YOUR GENEROSITY!!

“Our mission of helping the Greyhounds is supported by your kindness”.

To make a donation to the Greyhound Health and Wellness Program please use the link below to the secure website for online giving, or contact Dr. Guillermo Couto (couto.1@osu.edu) or Karen Longbrake (longbrake.1@osu.edu)

Thank you for your support!

www.giveto.osu.edu/igive/index2.asp?Project1=310050

The Ohio State University
Veterinary Teaching Hospital
601 Vernon L. Tharp Street.
Columbus, Ohio 43210
Companion Animal Ph: (614) 292-3551